










Received: 12 October 2024 · Accepted: 10 July 2025 · Published: 29 September 2025

Section editor: Peter Vďačný · Desk editor: Pepe Fernández

Research article

urn:lsid:zoobank.org:pub:E1DA282F-D967-43BF-9AA5-AFAF0C591BE6

***Myxobolus wondjii* sp. nov. (Myxozoa: Myxobolidae), a parasite of *Labeo batesii* Boulenger, 1911 (Teleostei: Cyprinidae) from the Makombè River, Cameroon: Morphological and molecular characterization**

Guy Benoît LEKEUFACK-FOLEFACK¹ , Bienvenu FEUDJIO-DONGMO² ,
Billy TENE-FOSSOG³ , Murielle J. WONDJI⁴ , Abraham FOMENA⁵ ,
Violetta YURAKHNO⁶ , Christopher M. WHIPPS⁷ ,
Saleh ALQURASHY⁸  & Lamjed MANSOUR^{9,*} 

^{1,5}Laboratory of Parasitology and Ecology, Department of Animal Biology and Physiology,
Faculty of Sciences, University of Yaoundé I, P.O. Box 812, Yaoundé, Cameroon.

²Department of Life Science, Higher Teacher Training College, University of Bertoua,
P.O. Box 652, Bertoua, Cameroon.

^{3,4}Centre for Research in Infectious Diseases, P.O. Box 13501, Yaoundé, Cameroon.

^{3,4}Vector Biology Department, Liverpool School of Tropical Medicine, Pembroke Place,
Liverpool L3 5QA, United Kingdom.

⁶A.O. Kovalevsky Institute of Biology of the Southern Seas, Russian Academy of Sciences,
2 Nakhimov Av., 299011, Sevastopol, Russian Federation.

⁷College of Environmental Science and Forestry, Environmental Biology, State University of New York,
1 Forestry Drive, Syracuse, New York 13210, United States.

^{8,9}Department of Zoology, College of Science, King Saud University, P.O. Box 2455,
11451 Riyadh, Saudi Arabia.

*Corresponding author: lmansour@ksu.edu.sa and lamjed.mansour@gmail.com

¹Email: leguyzo@yahoo.fr

²Email: feudonbie91@yahoo.com

³Email: billy.tene@crid-cam.net

⁴Email: murielle.wondji@lstmed.ac.uk

⁵Email: abfomena@yahoo.com

⁶Email: viola_taurica@mail.ru

⁷Email: cwhipps@esf.edu

⁸Email: squraishy@ksu.edu.sa

Abstract. A new species of the genus *Myxobolus* Bütschli, 1882 (Myxosporea: Bivalvulida) is described based on morphology, histopathology, and small subunit ribosomal DNA (SSU rDNA) sequence data. *Myxobolus wondjii* sp. nov. was found infecting the gills of *Labeo batesii* Boulenger, 1911 from the Makombè River at Nkondjock, Cameroon. Large, subspherical, whitish plasmodia measuring 100–2000 µm in length and 60–1400 µm in width were observed. Histopathological examination revealed

plasmodia located in the interbranchial septum of the gill. Mature myxospores were ovoid, slightly tapering anteriorly, and with a broad, rounded posterior end. The myxospores measured 12.4 ± 0.1 (12.0–13.2) μm in length and 8.8 ± 0.07 (8.3–9.4) μm in width. The two polar capsules were ovoid and distinctly unequal in size, measuring 5.4 ± 0.50 (4.8–6.3) \times 3.2 ± 0.06 (2.7–3.7) μm for the larger capsule and 1.6 ± 0.06 (1.4–1.7) \times 1.0 ± 0.08 (0.9–1.1) μm for the smaller one. A partial SSU rDNA sequence was obtained from this new species, and phylogenetic analysis placed it as sister to *Myxobolus nkondjockei*, which also infects *L. batesii* in Cameroon.

Keywords. Cyprinid fish, Africa, freshwater, fish parasites, Myxosporea, SSU rDNA.

Lekeufack-Folefack G.B., Feudjio-Dongmo B., Tene-Fossog B., Wondji M.J., Fomena A., Yurakhno V., Whipps C.M., Alqurashy S. & Lamjed M. 2025. *Myxobolus wondjii* sp. nov. (Myxozoa: Myxobolidae), a parasite of *Labeo batesii* Boulenger, 1911 (Teleostei: Cyprinidae) from the Makombè River, Cameroon: Morphological and molecular characterization. *European Journal of Taxonomy* 1022: 1–18.
<https://doi.org/10.5852/ejt.2025.1022.3077>

Introduction

Myxozoans are a group of microscopic cnidarians that primarily parasitize fish, some of which are associated with host morbidity and mortality (Lom & Dyková 2006). In freshwater species where the life cycle is known, it involves two distinct stages: myxospores emerging from fish and actinospores from oligochaete worms. In marine environments, myxozoans typically utilize polychaete worms as invertebrate hosts (Okamura *et al.* 2015). Globally, over 2200 species of myxozoans have been classified into 64 genera and 17 families (Fiala *et al.* 2015). However, the known myxozoan fauna parasitizing freshwater fishes in Africa comprises only about 280 species. In Cameroon, more than 80 species have been reported, with half belonging to the genus *Myxobolus* Bütschli, 1882 (Deli *et al.* 2017). The genus *Myxobolus* includes more than 1027 described species, representing a large portion of known myxozoan diversity (Eiras *et al.* 2021). Infections by species of this genus are often histozoic, targeting the skin, muscles, gills, or digestive system (Eiras *et al.* 2005, 2014, 2021). *Myxobolus* myxospores are typically ellipsoid, ovoid, or orbicular in valvular view, and biconvex in sutural view. The shell valves are usually smooth and enclose two pyriform polar capsules, which are sometimes unequal in size (Lom & Dyková 2006).

Most myxozoan species are classified based solely on myxospore morphology (Fiala *et al.* 2015). However, due to similarities in shape and size among many species, morphology-based differentiation between congeners is often difficult and artificial (Molnár *et al.* 2010; Rocha *et al.* 2019; Miranda Dias Vieira *et al.* 2022; Okkay *et al.* 2024). To address this limitation, many authors have advocated for the integration of phenotypic and genetic data to improve the identification and classification of myxozoans. Molecular methods, primarily based on small subunit ribosomal DNA (SSU rDNA) sequences, enable the differentiation of morphologically similar species (Kent *et al.* 2001; Ferguson *et al.* 2008; Guo *et al.* 2018) and facilitate the study of phylogenetic relationships, host specificity, and tissue tropism (Eszterbauer 2004; Fiala *et al.* 2015). In Africa, molecular and phylogenetic data on myxozoans remain limited. The few available records from sub-Saharan Africa include *Myxobolus dibombensis* Lekeufack-Folefack, Abdel-Baki, Ateba, Fomena & Mansour, 2019, *M. opsaridiumi* Lekeufack-Folefack, Tchoutezo-Tiwa, Fomena & Mansour, 2021, *M. nkondjockei* Lekeufack-Folefack, Feudjio-Dongmo, Tene-Fossog, Fomena, Wondji, Al-Tamimi, Yurakhno & Mansour, 2022, and *M. makombensis* Feudjio-Dongmo, Lekeufack-Folefack, Tene-Fossog, Fomena, Wondji, Yurakhno & Mansour, 2022. This represents a promising area for future discovery, especially as DNA sequencing becomes more accessible and applicable to the likely high diversity of African myxozoans.

Fishes of the genus *Labeo* Cuvier, 1817 are cyprinids classified within the subfamily Labeoninae Bleeker, 1859. They are distributed across Africa and Southeast Asia, where they are valued as important food fish (Howes 1991; Skelton *et al.* 1991). The Makombè River, a major tributary of the Wouri Basin in Cameroon, supports a rich ichthyofauna, including *Labeo batesii* Boulenger, 1911. This species is locally prized for its flavor and nutritional value, serving as a source of protein, trace elements, and polyunsaturated fatty acids (Ruxton *et al.* 2005; Feudjio-Dongmo 2023). Due to its reproductive capacity, rapid growth, and commercial potential, *L. batesii* is also considered a promising candidate for aquaculture (Ayoade *et al.* 2008; Nwani *et al.* 2011). However, as emphasized by Lekeufack-Folefack & Fomena (2013), understanding the parasite biodiversity of wild fish populations is essential for assessing potential health risks in aquaculture systems.

The present study is part of an ongoing investigation aimed at characterizing myxozoan parasites in freshwater fishes of Cameroon. During this work, we identified a species of *Myxobolus* infecting the gill of *L. batesii* from the Makombè River. Based on tissue tropism, myxospore morphology and dimensions, and SSU rDNA sequence analysis, we propose that this organism represents a new species.

Material and methods

Fish sampling

A total of 515 specimens of *L. batesii*, locally known as “mangy mouth”, were captured using gill nets between May 2017 and July 2018 in the Makombè River at Nkondjock, Littoral Region, Cameroon (4°42'49"–4°54'36" N, 10°10'20"–10°15'41" E). The harvested fish (standard length: 12.0–19.5 cm) were transported on ice to the Laboratory of Parasitology and Ecology at the University of Yaoundé I, Cameroon. Species identification was performed following Stiasny *et al.* (2007).

Morphological and histological analysis

External organs of *L. batesii*, including the eyes, operculum, scales, skin, and fins, were initially examined for the presence of plasmodia by direct observation and under an Olympus BO61 binocular stereoscopic microscope. Internal organs (kidney, bile duct, liver, gall bladder, digestive tract, spleen, heart, gonads, urinary duct, urethras, and muscles) were then dissected and examined under the same microscope. Smears from the kidney, spleen, liver, gonads, heart, and urethra were examined under a 40× objective using an IVYMEN light microscope.

To assess the gill plasmodia index, the average number of plasmodia on one side of the gill was estimated. Infection intensity was categorized as light (1–5 plasmodia), moderate (6–10 plasmodia), heavy (11–20 plasmodia), or severe (21 or more plasmodia), following Kaur & Attri (2015). Fresh plasmodia were isolated for morphological and molecular analyses. Morphometric characterization of 50 mature myxospores was performed under a 100× objective using an IVYMEN light microscope, following Lom & Arthur (1989). Some smears were fixed in methanol and stained with May-Grünwald-Giemsa (Piaton *et al.* 2015). Both fresh and stained myxospores were photographed using an Olympus BH-2 microscope (Olympus Optical Co., Ltd, Tokyo, Japan) equipped with a digital camera.

Histological sections were prepared from parasitized gill tissues. Infected gills were fixed in 10% neutral buffered formalin and processed using standard histological protocols as described by Wolfe (2019).

Molecular characterization and phylogenetic analysis

Genomic DNA was extracted from ethanol-preserved plasmodia using the optimized Livak protocol (Lekeufack-Folefack *et al.* 2020). A partial SSU rDNA sequence was amplified using the primers MC5 (5'-CCT GAG AAA CGG CTA CCA CAT CCA-3') and MC3 (5'-GAT TAG CCT GAC AGA TCA CTC CAC GA-3') (Molnár *et al.* 2002) in a Bioer Gene Touch Thermocycler (Dutscher). PCR reactions

were prepared in a 15 µl volume, containing 1.5 µl (50–200 ng) of extracted DNA, 0.2 µM of each primer, and 7.5 µl of OneTaq® Quick-Load® 2X Master Mix (New England Biolabs, Canada). The amplification protocol consisted of an initial denaturation at 9°C for 5 min, followed by 35 cycles of 95°C for 60 s, 60°C for 60 s, and 72°C for 90 s, with a final extension at 72°C for 5 min (Adriano *et al.* 2012). PCR products were visualized by electrophoresis on a 1.5% agarose gel (3 µl aliquots), and the remaining product was purified using a QIAquick PCR Purification Kit (QIAGEN, USA) according to the manufacturer’s instructions. Sequencing was performed by Genewiz (Liverpool, United Kingdom) using the same primers. Forward and reverse sequences were assembled and edited in BioEdit ver. 7.1.8.0 (Hall 1999). Sequence similarity was assessed using the NCBI Basic Local Alignment Search Tool (BLASTn) (Altschul *et al.* 1997).

Taxon selection for the phylogenetic analysis included 38 species of *Myxobolus* identified based on BLAST search results as closest relatives of *Myxobolus wondjii* sp. nov., along with four species from Cameroon (Lekeufack-Folefack *et al.* 2019, 2021, 2022; Feudjio-Dongmo *et al.* 2022). The sequence of *Myxobilatus gasterostei* Atkinson & Bartholomew, 2009 (GenBank accession number: EU861210) was used as an outgroup. Nucleotide sequences were aligned using ClustalW with default parameters in the BioEdit program (Hall 1999). The resulting alignment was trimmed in BioEdit and exported as FASTA and NEXUS files. The final dataset comprised 796 aligned nucleotide positions.

Phylogenetic relationships were analyzed using Bayesian Inference (BI) and Maximum Likelihood (ML). BI analysis was conducted in MrBayes ver. 3.2.7 (Ronquist *et al.* 2012) for 3.5 million generations using a Markov Chain Monte Carlo (MCMC) algorithm with two independent runs, each consisting of four simultaneous chains (nchains = 4). Trees were sampled every 175 generations (samplefreq = 175), and the first 25% of trees from each run were discarded as burn-in to ensure sampling at stationarity. The remaining trees were used to estimate posterior probabilities for the nodes. ML analysis was performed using RAxML ver. 8.2.9 (Kozlov *et al.* 2019) via the online platform, with bootstrap support values calculated from 1000 pseudoreplicates. Both BI and ML analyses were conducted under the GTR+I+G model, selected using jModelTest ver. 2.1.10 (Darriba *et al.* 2012) based on the Akaike Information Criterion (AIC). Phylogenetic trees were visualized using FigTree ver. 1.4.3 (Rambaut 2016) and edited in Adobe Illustrator (Adobe Systems, San Jose, CA, USA).

Abbreviations

BI	=	Bayesian inference
IBS	=	interbranchial septum
ICA	=	intercapsular appendix
IS	=	Immature myxospores
LPC	=	length of polar capsules
MCMC	=	Markov Chain Monte Carlo
ML	=	maximum likelihood
MS	=	mature myxospores
P	=	plasmodium
PC	=	relative length of the polar capsules
PCR	=	polymerase chain reaction
PT	=	number of coils of polar tubule
SL	=	spore length
SSU rDNA	=	small subunit ribosomal DNA
SW	=	spore width
WPC	=	width of polar capsules

Results

Systematic account

Phylum Cnidaria Hatschek, 1888
Subphylum Myxozoa Grassé, 1970
Class Myxosporea Bütschli, 1881
Order Bivalvulida Shulman, 1959
Suborder Platysporina Kudo, 1919
Family Myxobolidae Thélohan, 1892
Genus *Myxobolus* Bütschli, 1882

Myxobolus wondjii sp. nov.

urn:lsid:zoobank.org:act:8A6EF76D-A64D-4BFB-8814-74069C78D409

Figs 1–2; Table 1

Diagnosis

Myxospores 12.0–13.2 × 8.3–9.4 µm in size; ovoid, slightly tapering anteriorly and with a broad, rounded posterior end; polar capsules ovoid and markedly unequal in size: larger capsule 5.4 × 3.2 µm on average, containing a polar tubule coiled in 9 to 11 turns and occupying anterior half of myxospore cavity, while smaller capsule 1.6 × 1.0 µm on average, with no visible polar tubule and occupying approximately 1/10 of cavity length. Plasmodia large (100–2000 × 60–1400 µm), subspherical, whitish, and located in interbranchial septa of host gills.

Etymology

The specific epithet *wondjii* is given in honor of Wondji Charles Synclair, Professor at the Liverpool School of Tropical Medicine, United Kingdom.

Type material

Hapantotype

CAMEROON • gills of *Labeo batesii* Boulenger, 1911 infected with plasmodia (in Eppendorf tubes (50 ml) containing formalin-fixed); Littoral Region, Nkondjock, Makombè River; 4°42'49"–4°54'36" N, 10°10'20"–10°15'41" E; GenBank no PQ407595; parasitological collection of the Laboratory of Parasitology and Ecology, Faculty of Sciences, University of Yaoundé I, Cameroon No. Myxo/2024/LPE-002.

Taxonomic summary

Type locality

Makombè River, Nkondjock, Littoral Region, Cameroon, 4°42'49"–4°54'36" N, 10°10'20"–10°15'41" E.

Type host

Labeo batesii Boulenger, 1911 (Cyprinidae).

Site of infection

Gill, interbranchial septum.

Vegetative stages

Large, whitish, subspherical plasmodia of variable size were observed on the gills of 66 out of 515 examined specimens of *L. batesii*, corresponding to a prevalence of 12.8% (Fig. 1a–b). These plasmodia measured 100–2000 µm in length and 60–1400 µm in width. Up to 27 plasmodia were found per parasitized fish, with infections present on both gill arches. Development appeared asynchronous, as indicated by the presence of plasmodia of various sizes (Fig. 1a). The gill plasmodia index (mean ± SD)

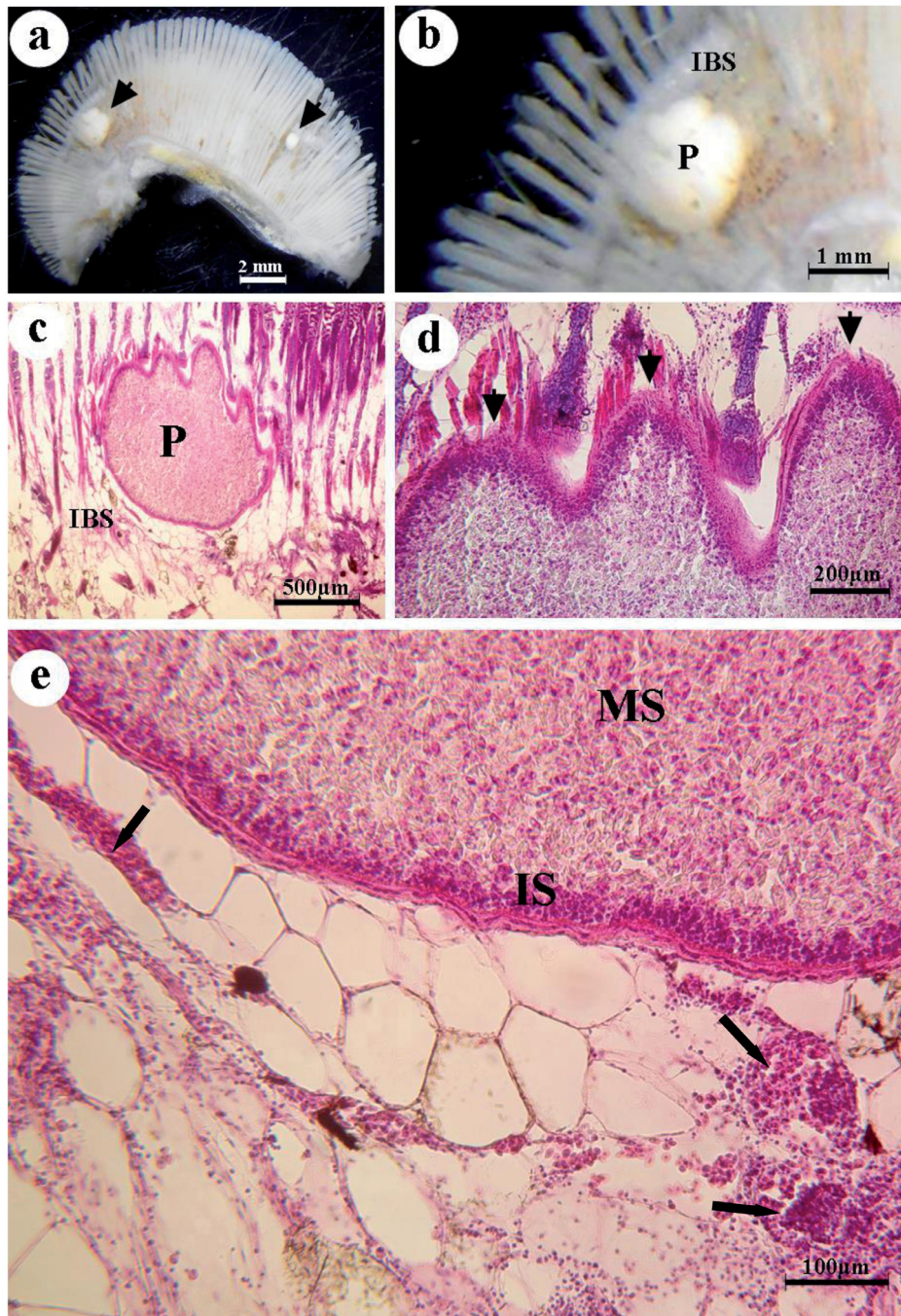


Fig. 1. Photomicrographs of gills of *Labeo batesii* Boulenger, 1911 showing plasmodia of *Myxobolus wondjii* sp. nov. **A.** Fresh preparation showing whitish plasmodia in the gills (arrowheads). **B.** High-magnification fresh preparation showing a plasmodium (P) located on the interbranchial septum (IBS). **C.** Histological section of gills stained with H&E showing the general morphology of the plasmodium (P) in the interbranchial septum (IBS). **D.** Histological section stained with H&E showing cyst protrusions (arrowheads). **E.** Histological section stained with H&E showing: lack of adhesion between tissue layers surrounding the plasmodium; influx of monocytes at the plasmodium periphery (arrows); multi-layered membrane surrounding the plasmodium; immature myxospores (IS) at the periphery and mature myxospores (MS) in the medial part of the plasmodium. Abbreviations: IBS = interbranchial septum; IS = immature myxospores; MS = mature myxospores; P = plasmodium.

was 2.3 ± 0.6 (range: 1–8), indicating a light infection. Overall, the intensity of infection was classified as light.

Description

Histological examination

Histological sections of the gills revealed that plasmodia were located in the connective tissue of the interbranchial septum (Fig. 1c). The plasmodia exhibited peripheral protrusions, likely resulting from modifications of the surrounding host tissues induced by their growth (Fig. 1d). At higher magnification (Fig. 1e), the parasitized tissue showed: (1) alteration and lack of adhesion between the tissue layers surrounding the plasmodium; (2) a multi-layered membrane enclosing the plasmodium, including an outer layer of collagen fibers; (3) presence of monocytes at the plasmodium periphery; and (4) immature myxospores in the peripheral zone and mature myxospores in the median zone of the plasmodium.

Mature myxospores

Myxospores were ovoid, slightly tapering anteriorly and with a broad, rounded posterior end (Fig. 2a). In sutural view, myxospores appeared biconvex (Fig. 2b). The valves were thick and smooth, with no apparent sutural ridge markings, though the suture line was prominent (Fig. 2b). Two apically oriented polar capsules were ovoid, markedly unequal in size and converging towards the apex of the myxospore (Fig. 2a, c–d). The large polar capsule was well developed ($5.4 \times 3.2 \mu\text{m}$ on average), containing a polar tubule coiled in 9 to 11 turns and occupying the anterior half of the myxospore cavity (Fig. 2d). The smaller polar capsule was extremely reduced ($1.6 \times 1.0 \mu\text{m}$ on average), occupying approximately $1/10$ of the cavity length, with no visible polar tubule (Fig. 2a, c–d). The remainder of the cavity was filled with sporoplasm, which contained an iodophilous vacuole of variable size, shape, and position (Fig. 2a, d). Mean myxospore dimensions are provided in Table 1.

Remarks

A striking feature of *M. wondjii* sp. nov. is the extremely reduced second polar capsule. While not unique among species of *Myxobolus*, this trait is unusual (Lom & Dyková 2006). Through examination of species synopses (Eiras *et al.* 2005, 2014, 2021) and database searches of more recent articles, we identified 20 species of *Myxobolus* with distinctly unequal polar capsules.

In some species (*Myxobolus buccoroofus* Basu & Haldar, 2004; *M. harikensis* Kaur & Singh, 2011; *M. mrigalhitae* Basu & Haldar, 2003; *Myxobolus patialensis* Kaur & Singh, 2011), the smaller polar capsule discharges away from the apex of the myxospore. In others, the smaller polar capsule discharges at the apex (*M. andhrae* (Lalitha Kumari, 1969); *M. bhadrensis* Seenappa & Manohar, 1981; *M. chilkenis* (Kalavati, Vankateswara Rao & Vaidachei, 1992); *M. duodenalis* Kaur & Singh, 2011; *M. goensis* Eiras & D'souza, 2004; *M. indicum* Tripathi, 1952; *M. labeoi* Boungou, Kabre Sakiti, Marques & Sawadogo, 2006; *M. paratoyamai* Kato, Kasai, Tomochi, Li & Sato, 2017; *M. paratypicus* Xi, Zhao, Li & Xie, 2019; *M. nchoutnounensis* Nchoutpouen & Fomena, 2011; *M. koli* Lalitha Kumari, 1969; *M. mahendrae* Sarkar, 1986; *M. mrigalae* Chakravarty, 1939; *M. saranai* (Tripathi, 1952); *M. undasuturiae* Sarkar, 1994; *M. analfinus* Basu, Modak & Haldar, 2009).

The species described here, *M. wondjii* sp. nov., appears to have a degenerate polar capsule with no visible polar tubule. This is most similar to *M. bhadrensis*, *M. chilkenis*, *M. duodenalis*, *M. indicum*, *M. labeoi*, *M. paratoyamai*, and *M. paratypicus* (Table 1). Several characteristics differentiate each of these from *M. wondjii* sp. nov.

Myxobolus bhadrensis was found in the muscle of *Labeo rohita* Hamilton, 1822 in India. Its myxospores are smaller, with a thickening anterior end, measuring on average $9.5 \times 7.1 \mu\text{m}$, and a larger polar capsule averaging $3.5 \times 2.2 \mu\text{m}$.

Myxobolus chilkinsis, a gall bladder parasite of *L. rohita* in India, has spherical to pyriform myxospores ($7.2\text{--}8.0 \times 5.6\text{--}6.6 \mu\text{m}$). Their polar capsules are pyriform, with the larger being $3.2\text{--}4.8 \times 1.8\text{--}2.2 \mu\text{m}$ in size, and the smaller having a narrow neck.

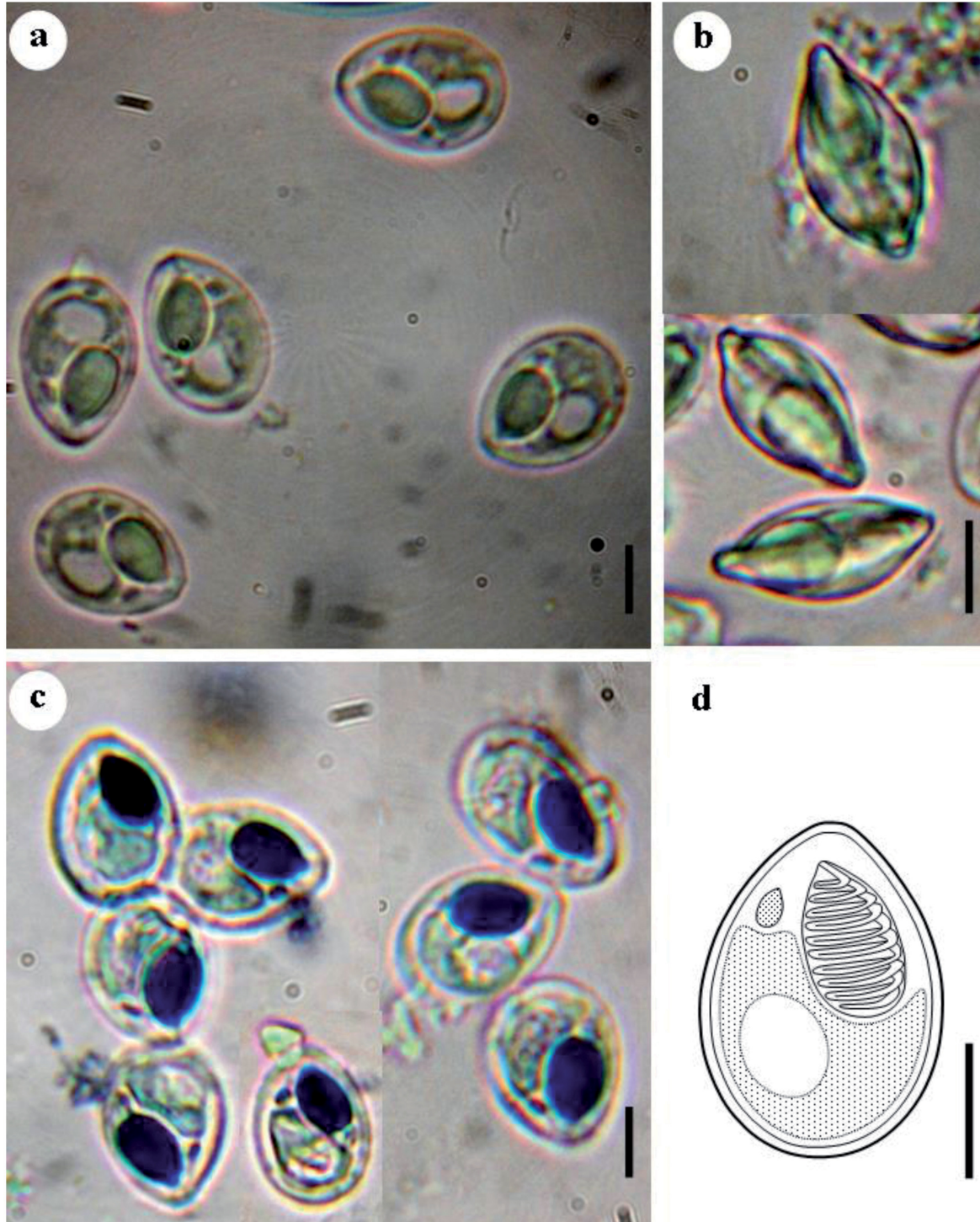


Fig. 2. Photomicrographs of mature myxospores of *Myxobolus wondjii* sp. nov. **A.** Myxospores in frontal view. **B.** Myxospores in lateral (sutural) view. **C.** Myxospores stained with May-Grünwald-Giemsa. **D.** Diagrammatic drawing of a myxospore in valvular view. Scale bars = 5 μm .

Table 1. Comparison of *Myxobolus wondjii* sp. nov. with morphologically similar species of *Myxobolus*. Myxospore dimensions are given in micrometers (μm). Arithmetic means are followed by ranges in parentheses. Abbreviations: ICA = intercapsular appendix; LPC = length of polar capsules; PC = relative length of polar capsules; PT = number of coils of polar tubule; SL = spore length; SW = spore width; WPC = width of polar capsules; * = relative to the large polar capsule; ** = relative to the small polar capsule; / = data not available.

Parasite species	Host species	Infestation site	Country	SL	SW	PC	LPC	WPC	PT	ICA	Reference
<i>Myxobolus wondjii</i> sp. nov.	<i>Labeo batesii</i>	Gills	Cameroon	12.4 \pm 0.1 (12–13.2)	8.8 \pm 0.07 (8.3–9.4)	Unequal	5.4 \pm 0.5 (4.8–6.3)* 1.6 \pm 0.06 (1.4–1.7)**	3.2 \pm 0.06 (2.7–3.7)* 1.1 \pm 0.08 (0.9–1.1)**	9–11* / **	Absent	Present study
<i>M. bhadransis</i>	<i>Labeo rohita</i>	Muscle	India	9.5 (8.0–11.0)	7.1 (7.0–8.0)	Unequal	3.5 (3.0–4.0)* 2.5 (2.0–4.0)**	2.2 (2.0–3.0)* 1.7 (1.0–2.0)**	/	Absent	Seenappa & Manohar (1981)
<i>M. chilkenis</i>	<i>Labeo rohita</i>	Gill	India	7.7 (7.2–8.0)	6.2 (5.6–6.6)	Unequal	4.2 (3.2–4.8)* 1.0 (1.0–1.2)**	1.98 (1.8–2.2)* / **	/	Absent	Kalavati <i>et al.</i> (1992) Kalavati & Nandi (2007)
<i>M. duodenalis</i>	<i>Wallago attu</i>	Duodenum	India	9.0 (8.5–9.5)	3.2 (2.7–3.7)	Unequal	4.7 (4.0–5.4)* 2.7 (2.2–3.2)**	1.7 (1.36–2.16)* 1.0 (0.5–1.5)**	6–7* / **	Absent	Kaur & Singh (2011)
<i>M. indicum</i>	<i>Cirrhina mrigala</i>	Muscles, liver, intestine	India	9.5–10.8	7.5–8.2		2.7–3.6* 1.8**	1.8* 1.0**	/	Absent	Tripathi (1952)
<i>M. labeoi</i>	<i>Labeo coubie</i>	Between fin rays	Burkina Faso	16.4 (16.0–17.0)	10.7 (10.0– 12.0)	Unequal	8.3 (7.0–9.0)* 1.5 (1.6–2.0)**	6.5 (5–7)* 0.4 (0.3–0.5)**	10* / **	Absent	Boungou <i>et al.</i> (2006)
<i>M. paratoyamai</i>	<i>Cyprinus carpio</i>	Gills	Japan	15.4 (14.7–16.4)	6.3 (5.5–6.8)	Unequal	6.5 (5.9–7.1)* / **	3.7 (3.1–4.2)* / **	5–6* / **	Absent	Kato <i>et al.</i> (2017)
<i>M. paratypicus</i>	<i>Hypophthalmichthys molitrix</i>	Gills	China	13.8 (12.9–14.9)	9.9 (9.2–11.1)	Unequal	7.5 (6.2–8.2)* 2.7 (2.1–3.6)**	5.0 (4.2–5.6)* 1.4 (1.1–1.9)**	7–8* / **	Absent	Fomena & Bouix (1994)

Myxobolus duodenalis, which parasitizes the inner wall of the duodenum of *Wallago attu* Bloch & Schneider, 1801 in India, forms smaller myxospores ($9.0 \times 3.2 \mu\text{m}$ on average). Its larger polar capsule occupies more than half of the myxospore cavity, and the smaller one about one-third.

Myxobolus indicum infects various organs of *Cirrhinus mrigala* Hamilton, 1822 in India. The larger polar capsule of *M. wondjii* sp. nov. is longer ($4.8\text{--}6.3 \mu\text{m}$) than that of *M. indicum* ($2.7\text{--}3.6 \mu\text{m}$).

Myxobolus labeoi, a parasite of the fins of *Labeo coubie* Rüppell, 1832 in Burkina-Faso, has longer myxospores ($16\text{--}17 \mu\text{m}$) and larger polar capsules (average $8.37 \times 6.53 \mu\text{m}$).

Myxobolus paratoyamai, a gill parasite of *Cyprinus carpio* Linnaeus, 1758 in Japan, differs by its elongated pyriform myxospore with a slightly bent anterior end.

Myxobolus paratypicus, a gill parasite of *Hypophthalmichthys molitrix* (Valenciennes, 1844) in China, has larger myxospores ($13.8 \times 9.9 \mu\text{m}$ on average) and a larger polar capsule ($6.2\text{--}8.2 \times 4.2\text{--}5.6 \mu\text{m}$) that extends beyond the midpoint of the myxospore body.

It is also worthwhile to compare this new species of *Myxobolus* to *Thelohanellus sanagaensis* Fomena, Marques, Bouix & Njiné, 1994, described from the gills of an unidentified *Labeo* species in Cameroon (Fomena *et al.* 1994). Although the spores overlap in size and general appearance, *T. sanagaensis* has only one polar capsule.

SSU rDNA sequence data

The primer sets MC5F and MC3R successfully amplified a 1046 bp fragment of SSU rDNA for *Myxobolus wondjii* sp. nov. Based on the BLASTn search, this sequence did not match any publicly available myxozoan species. The highest nucleotide similarity was 96.1% with *M. nkondjockei* (accession number: ON158090), which was reported to infect the scales of the same host, *Labeo batesii* (Cyprinidae). Similarity with other myxozoan species was $\leq 92\%$. Comparisons with species recently sequenced from freshwater fish in Cameroon revealed the following similarities: 81.4% with *M. dibombensis*; 82% with *M. opsaridiumi*; and 84.5% with *M. makombensis*.

Phylogenetic analysis

Trees generated by ML and BI methods exhibited similar topologies, with some differences in support values. Two main monophyletic clades, designated A and B, were recognizable in the consensus tree (Fig. 3). *Myxobolus wondjii* sp. nov. clustered within clade B, which primarily comprised species of *Myxobolus* infecting cyprinids from China. The new species is sister to *M. nkondjockei* (accession number: ON158090), previously reported from the scales of *Labeo batesii* in Cameroon (Lekeufack-Folefack *et al.* 2022). These two species, in turn, form a sister group with *Myxobolus* sp. (accession number: OP358475), reported from the gills of *Labeo rohita* in India. The sister-group relationship between *M. wondjii* and *M. nkondjockei* is notable, as both infect the same host species in the same geographic region, albeit in different tissues. This cluster of three species, along with two additional myxobolids, forms a sister group to a larger clade composed mostly of species reported from China. Other species of *Myxobolus* collected from Cameroon are found in clade A (Fig. 3), including *M. dibombensis* (accession number: MG737377) and *M. makombensis* (accession number: MZ701982), which parasitize the fins and gills, respectively, of *Labeobarbus batesii*. Clade C includes species infecting marine fishes.

Discussion

The myxospore morphology of the species described in this study is consistent with the diagnostic characteristics of the genus *Myxobolus* (Lom & Dyková 2006). Although polar capsules of unequal size are not uncommon in this genus, *M. wondjii* sp. nov. is notable for having one greatly reduced polar

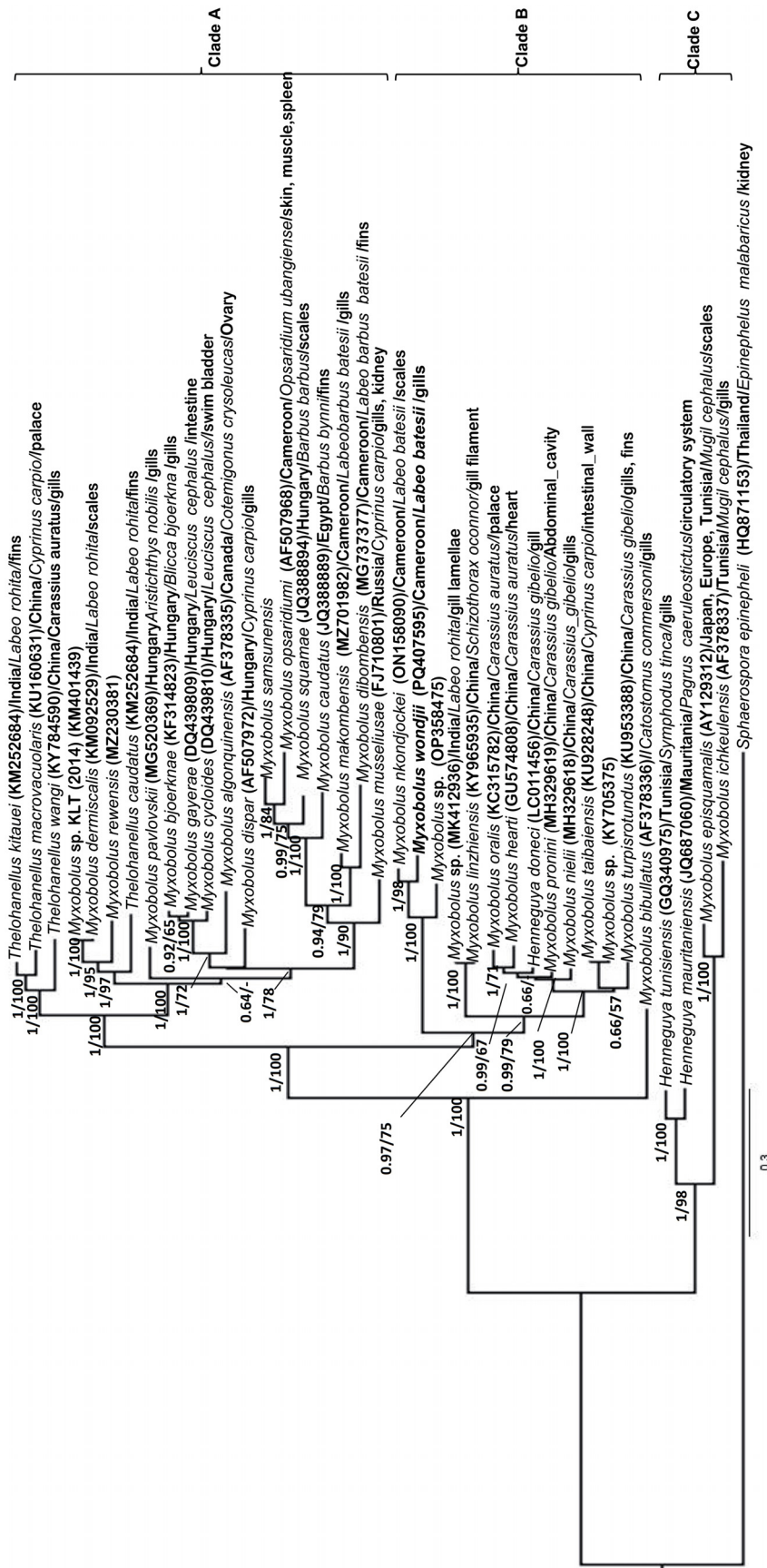


Fig. 3. Phylogenetic tree generated by Bayesian Inference (BI) analysis based on SSU rDNA sequences of *Myxobolus wondjii* sp. nov. and related myxosporean species. GenBank accession numbers, geographic origin, host species, and infection sites are indicated. Support values at nodes are shown as Bayesian posterior probabilities / ML bootstrap values. Dashes indicate support values below 50%. *Myxobolatus gasterostei* Atkinson & Bartholomew, 2009 was used as the outgroup. *Myxobolus wondjii* is shown in bold.

capsule. Based on our observations, there is no evidence of a polar tubule within this smaller capsule. This feature is shared with species such as *M. bhadrensis* (Seenappa & Manohar 1981), *M. chilkinsis* (Kalavati & Nandi 2007), *M. duodenalis* (Kaur & Singh 2011), *M. indicum* (Tripathi 1952), *M. labeoi* (Boungou *et al.* 2006), *M. paratoyamai* (Kato *et al.* 2017), and *M. paratypicus* (Xi *et al.* 2019). The presence of a diminutive polar capsule alongside a larger one gives *M. wondjii* a resemblance to species of *Thelohanellus* Kudo, 1933, which are morphologically similar to *Myxobolus* but possess only a single polar capsule (Lom & Dyková 2006). In a comprehensive phylogenetic study, Zhang *et al.* (2019) proposed that species of *Thelohanellus* have diverged from *Myxobolus* ancestors multiple times during myxozoan evolution. The reduced polar capsule in *M. wondjii* may represent a case of gradual degeneration, particularly if it is non-functional, potentially reflecting a similar evolutionary trajectory. It is also noteworthy that *T. sanagaensis* was described from the gills of an unidentified species of *Labeo*, while *M. wondjii* was found in *L. batesii*. The key morphological distinction is the presence of a second polar capsule in *M. wondjii*, which is absent in *T. sanagaensis*. While this difference could represent intraspecific variation, the lack of genetic data for *T. sanagaensis* warrants maintaining them as separate species for now. Several studies based on SSU rDNA sequence analysis have shown that phylogenetic reconstructions do not support the monophyly of the genera *Myxobolus*, *Henneguya* Thélohan, 1892, and *Thelohanellus* (Smothers *et al.* 1994; Andree *et al.* 1999; Liu *et al.* 2010, 2019; Mansour *et al.* 2021). Although this lack of monophyly is well recognized, it presents a challenge for systematists, as these genera are species-rich and intermixed, with no clear phylogenetically consistent boundaries.

In our SSU rDNA phylogenetic analysis, *M. wondjii* sp. nov. showed 96.1% similarity and a sister-group relationship to *M. nkondjockei*, which infects the scales of *L. batesii* in Cameroon (Lekeufack-Folefack *et al.* 2022), followed by 93.5% similarity with an unidentified *Myxobolus* sp. from the gills of *L. rohita* in India. Numerous species of *Myxobolus* have been described from cyprinid fishes, with at least 45 species reported from *Labeo* (Eiras *et al.* 2005, 2014, 2021). Of the eleven species of *Myxobolus* known to infect species of *Labeo* in Africa, only *Myxobolus magai* (Deli *et al.* 2017) and *M. nkondjockei* (Lekeufack-Folefack *et al.* 2022) have been recorded from *L. batesii* in Cameroon. *Myxobolus wondjii* is therefore the third species reported from this host.

Our phylogenetic tree recovered two major clades, A and B, composed of freshwater species, while the few marine species included were grouped in clade C. This pattern is consistent with previous studies (Kent *et al.* 2000; Fiala 2006; Carriero *et al.* 2013; Rocha *et al.* 2019; Lekeufack-Folefack *et al.* 2021; Feudjio-Dongmo *et al.* 2022). The clustering observed supports the hypothesis that host phylogeny is a major factor influencing myxobolid relationships. However, geographic distribution also plays a role, as previously suggested (Urawa *et al.* 2011; Adriano *et al.* 2012; Hartigan *et al.* 2012; Kato *et al.* 2017; Lekeufack-Folefack *et al.* 2019).

Regarding tissue specificity, identifying the precise site of infection is crucial for understanding potential evolutionary relationships. Molnár (2002) categorized gill-infecting myxozoans into four site types: vascular, epithelial, connective tissue, and cartilage. However, *M. wondjii* sp. nov. was found in the interbranchial septum of *L. batesii*, a location that does not clearly fit into any of these established categories. It is possible that smaller plasmodia may have originated in more typical sites, but based on our findings, we propose that the interbranchial septum be recognized as a potential site of myxozoan infection. The degree of pathology caused by gill-infecting myxozoans varies (Dyková & Lom 1978). Some species form tiny, inconspicuous plasmodia (Deli *et al.* 2017; Feudjio-Dongmo *et al.* 2022), while others, like *M. wondjii*, form large plasmodia several millimeters in diameter. The variation in plasmodium size suggests asynchronous development. The plasmodium wall consisted of two layers: an inner layer likely of parasite origin, derived from the eosinophilic ectoplasm of the plasmodium (cf. Feist *et al.* 2015), and an outer layer of host origin, composed of collagen fibers associated with the surrounding connective tissue. Plasmodia also exhibited protrusion, possibly resulting from mechanical

pressure exerted during growth, causing localized deformation. Similar protrusions have been observed in infections by *Henneguya psorospermica* Thélohan, 1892 (Dyková & Lom 1978) and *Myxobolus intimus* Zaika, 1965 (Rácz *et al.* 2004). Given the size and location of the plasmodia, *M. wondjii* may impair gill function and reduce the respiratory surface of *L. batesii*. Further studies are needed to evaluate this potential impact.

Acknowledgments

The authors extend their appreciation to the Ongoing Research Funding program (ORF-2025-75), King Saud University, Riyadh, Saudi Arabia. Part of the work carried out by V. M. Yurakhno was supported within the framework of IBSS state research assignment “Biodiversity as the basis for the sustainable functioning of marine ecosystems, criteria and scientific principles for its conservation” (No. 124022400148-4), Russian Federation.

References

- Adriano E.A., Carriero M.M., Maia A.A.M., Silva M.R.M.D., Naldoni J., Ceccarelli P.S. & Arana S. 2012. Phylogenetic and host-parasite relationship analysis of *Henneguya multiplasmodialis* n. sp. infecting *Pseudoplatystoma* spp. in Brazilian Pantanal wetland. *Veterinary Parasitology* 185: 110–120. <https://doi.org/10.1016/j.vetpar.2011.10.008>
- Altschul S.F., Madden T.L., Schäffer A.A., Zhang J., Zhang Z., Miller W. & Lipman D.J. 1997. Gapped BLAST and PSI-BLAST: a new generation of protein database search programs. *Nucleic Acids Research* 25 (17): 3389–3402. <https://doi.org/10.1093/nar/25.17.3389>
- Andree K.B., Székely C., Molnár K., Gresoviac S.J. & Hedrick R.P. 1999. Relationships among members of the genus *Myxobolus* (Myxozoa: Bilvalvidae) based on small subunit ribosomal DNA sequences. *Journal of Parasitology* 85: 68–74. <https://doi.org/10.2307/3285702>
- Ayoade A., Fagade S. & Adebisi A. 2008. Diet and dietary habits of the fish *Schilbe mystus* (Siluriformes: Schilbeidae) in two artificial lakes in Southwestern Nigeria. *Revista de Biología tropical* 56: 1847–1855. <https://doi.org/10.15517/rbt.v56i4.5764>
- Boungou M., Kabre G.B., Sakiti N.G., Marquès A. & Sawadogo L. 2006. Description of four new myxosporean species (Myxozoa: Myxosporea) from genus *Myxobolus*, fish parasites of Burkina-Faso, West Africa. *Journal of Biological Sciences* 6 (5): 861–867. <https://doi.org/10.3923/jbs.2006.861.867>
- Carriero M.M., Adriano E.A., Silva M.R., Ceccarelli P.S. & Maia A.A. 2013. Molecular phylogeny of the *Myxobolus* and *Henneguya* genera with several new South American species. *PLoS ONE* 8 (9): e73713. <https://doi.org/10.1371/journal.pone.0073713>
- Darriba D., Taboada G.L., Doallo R. & Posada D. 2012. jModelTest 2: more models, new heuristics and parallel computing. *Nature Methods* 9: 772. <https://doi.org/10.1038/nmeth.2109>
- Deli A., Lekeufack Folefack G.B. & Fomena A. 2017. Description of *Myxidium tetraodoni* sp. nov., *Myxidium anisocapsularis* sp. nov. and *Myxobolus magai* sp. nov. (Myxosporea: Bivalvulida) infecting some freshwater fishes in Cameroon (Central Africa). *Fisheries and Aquaculture Journal* 8 (4): 1–10. <https://doi.org/10.4172/2150-3508.1000235>
- Dyková I. & Lom J. 1978. Histopathological changes in fish gills infected with myxosporidian parasites of the genus *Henneguya*. *Journal of Fish Biology* 12 (3): 197–202. <https://doi.org/10.1111/j.1095-8649.1978.tb04165.x>
- Eiras J.C. & D’Souza J. 2004. *Myxobolus goensis* n. sp. gills of (Myxozoa, Myxosporea, Myxobolidae), a parasite of the gills of *Mugil cephalus* (Osteichthyes, Mugilidae) from Goa, India. *Parasite* 11 (3): 243–248. <https://doi.org/10.1051/parasite/2004113243>

- Eiras J.C., Molnár K. & Lu Y.S. 2005. Synopsis of the species of *Myxobolus* Bütschli, 1882 (Myxozoa: Myxosporea: Myxobolidae). *Systematic Parasitology* 61: 1–46. <https://doi.org/10.1007/s11230-004-6343-9>
- Eiras J.C., Zhang J. & Molnár K. 2014. Synopsis of the species of *Myxobolus* Bütschli, 1882 (Myxozoa: Myxosporea, Myxobolidae) described between 2005 and 2013. *Systematic Parasitology* 88: 11–36. <https://doi.org/10.1007/s11230-014-9484-5>
- Eiras J.C., Cruzl F.C., Saraiva A. & Adriano E.A. 2021. Synopsis of the species of *Myxobolus* (Cnidaria, Myxozoa, Myxosporea) described between 2014 and 2020. *Folia Parasitologica* 68: 12–19. <https://doi.org/10.14411/fp.2021.012>
- Eszterbauer E. 2004. Genetic relationship among gill-infecting *Myxobolus* species (Myxosporea) of cyprinids: molecular evidence of importance of tissue-specificity. *Diseases of Aquatic Organisms* 58: 35–40. <https://doi.org/10.3354/dao058035>
- Feist S.W., Morris D.J., Alama-Bermejo G. & Holzer A.S. 2015. Cellular processes in myxozoans. In: Okamura B., Gruhl A. & Bartholomew J.L. (eds) *Myxozoan Evolution, Ecology and Development*: 139–154. Springer, Cham. https://doi.org/10.1007/978-3-319-14753-6_8
- Ferguson J.A., Atkinson S.D., Whipps C.M. & Kent M.L. 2008. Molecular and morphological analysis of *Myxobolus* spp. of salmonid fishes with the description of a new *Myxobolus* species. *Journal of Parasitology* 94: 1322–1334. <https://doi.org/10.1645/GE-1606.1>
- Feudjio-Dongmo B. 2023. *Myxosporidia (Cnidaria: Myxosporea) Parasites of Labeo batesii Boulenger, 1911 and Labeobarbus batesii (Boulenger, 1903) (Teleostei: Cyprinidae) of the Makombè River at Nkondjock in the Littoral Region, Cameroon: Phenotypic, Molecular, Phylogenetic and Bio-ecological characterizations*. Ph.D thesis, University of Yaoundé I.
- Feudjio-Dongmo B., Lekeufack-Folefack G.B., Tene-Fossog B., Fomena A., Wondji C.S., Yurakhno V.M., Alomar S. & Mansour L. 2022. *Myxobolus makombensis* n. sp. infection in African carp *Labeobarbus batesii* from the Makombè River, Cameroon: morphological and molecular characterization. *Diseases of Aquatic Organisms* 151: 75–84. <https://doi.org/10.3354/dao03691>
- Fiala I. 2006. The phylogeny of Myxosporea (Myxozoa) based on small subunit ribosomal RNA gene analysis. *International Journal for Parasitology* 36: 1521–1534. <https://doi.org/10.1016/j.ijpara.2006.06.016>
- Fiala I., Bartošová P. & Whipps C.M. 2015. Classification and phylogenetics of Myxozoa. In: Okamura B., Gruhl A. & Bartholomew J.L. (eds) *Myxozoan Evolution, Ecology and Development*: 85–110. Springer, Cham. https://doi.org/10.1007/978-3-319-14753-6_5
- Fomena A. & Bouix G. 1994. New Myxosporidia species (Myxozoa) from freshwater teleosts in Southern Cameroon (central Africa). *Journal of African Zoology* 108: 481–491.
- Fomena A., Marques A., Bouix G. & Njiné T. 1994. *Myxobolus bilongi* n. sp., *Thelohanellus assambai* n. sp. et *Thelohanellus sanagaensis* n. sp., myxosporidies parasites de *Labeo* sp. (Téléostéen Cyprinidae) du Bassin de la Sanaga au Cameroun (Afrique Centrale). *Annales de la Faculté des Sciences Yaoundé* 3: 131–142.
- Guo Q., Huang M., Liu Y., Zhang X. & Gu Z. 2018. Morphological plasticity in *Myxobolus* Bütschli, 1882: a taxonomic dilemma case and renaming of a parasite species of the common carp. *Parasites & Vectors* 11: e399. <https://doi.org/10.1186/s13071-018-2943-0>
- Hall T.A. 1999. BioEdit: a user-friendly biological sequence alignment editor and analysis program for Windows 95/98/NT. *Nucleic Acids Symposium Series* 41: 95–98.

- Hartigan A., Fiala I., Dyková I., Rose K., Phalen D.N. & Šlapeta J. 2012. New species of Myxosporea from frogs and resurrection of the genus *Cystodiscus* Lutz, 1889 for species with myxospores in gallbladders of amphibians. *Parasitology* 139: 478–496. <https://doi.org/10.1017/S0031182011002149>
- Howes G.J. 1991. Systematics and biogeography: An overview. *In*: Winfield I.J. & Nelson J.S. (eds) *Cyprinid Fishes—Systematics, Biology and Exploitation*: 1–33. Chapman & Hall, London. https://doi.org/10.1007/978-94-011-3092-9_1
- Kalavati C. & Nandi N.C. 2007. *Handbook on Myxosporean Parasites of Indian Fishes*. Zoological Survey of India, Kolkata.
- Kalavati C., Rao J.V. & Vaidehi J. 1992. Myxosporidian parasites (Protozoa) of fishes of Chilka Lake, east coast of India: three new species of *Henneguya* Thélohan, *Rudicapsula* Kalavati and *Narasimhamurti* and *Unicauda* Auerbach. *Indian Journal of Parasitology* 16: 77–83.
- Kato E., Kasai A., Tomochi H., Li Y.-C. & Sato H. 2017. Four *Myxobolus* spp. (Myxosporea: Bivalvulida) from the gill lamellae of common carp (*Cyprinus carpio*) and Japanese silver crucian carp (*Carassius langsdorfii*) in the western part of Japan, with the description of three new species (*M. tanakai* n. sp., *M. paratoyamai* n. sp., and *M. ginbuna* n. sp.). *Parasitology Research* 116: 2427–2441. <https://doi.org/10.1007/s00436-017-5545-4>
- Kaur H. & Attri R. 2015. Morphological and molecular characterization of *Henneguya bicaudi* n. sp. (Myxosporea: Myxobolidae) infecting gills of *Cirrhinus mrigala* (Ham.) in Harike Wetland, Punjab (India). *Parasitology Research* 114: 4161–4167. <https://doi.org/10.1007/s00436-015-4647-0>
- Kaur H. & Singh R. 2011. Two new species of *Myxobolus* (Myxozoa: Myxosporea: Bivalvulida) infecting Indian freshwater fishes in Punjab wetlands (India). *Parasitology Research* 108: 1075–1082. <https://doi.org/10.1007/s00436-011-2307-6>
- Kent M.L., Khattra J., Hedrick R.P. & Devlin R.H. 2000. *Tetracapsula renicola* n. sp. (Myxozoa: Saccosporidae); the PKX myxozoan—the cause of proliferative kidney disease of salmonid fishes. *Journal of Parasitology* 86 (1): 103–111. [https://doi.org/10.1645/0022-3395\(2000\)086\[0103:TRNSMS\]2.0.CO;2](https://doi.org/10.1645/0022-3395(2000)086[0103:TRNSMS]2.0.CO;2)
- Kent M., Andree K., Bartholomew J.L., El-Matbouli, M., Desser S.S., Delving R.H., Feist S.W., Hedrick R.P., Hoffman R.W., Khattra J., Hallet S.L., Lester R.J.G., Longshaw M., Palenzuela O., Sidal M.E. & Xiao C. 2001. Recent advances in our knowledge of the Myxozoa. *Journal of Eukaryotic Microbiology* 49: 395–413. <https://doi.org/10.1111/j.1550-7408.2001.tb00173.x>
- Kozlov A.M., Darriba D., Flouri T., Morel B. & Stamatakis A. 2019. RAxML-NG: a fast, scalable and user-friendly tool for maximum likelihood phylogenetic inference. *Bioinformatics* 35: 4453–4455. <https://doi.org/10.1093/bioinformatics/btz305>
- Lalitha Kumari P.S. 1969. Studies on parasitic protozoa (Myxosporidia) of fresh water fishes of Andhra Pradesh, India. *Rivista di Parassitologia* 30 (3): 153–226.
- Lekeufack-Folefack G.B. & Fomena A. 2013. Structure et dynamique des infracommunautés de myxosporidies parasites de *Ctenopoma petherici* Günther, 1864 (Anabantidae), *Clarias pachynema* Boulenger, 1903 (Clariidae) et *Hepsetus odoe* (Bloch, 1794) (Hepsetidae) dans la rivière Sangé au Cameroun. *International Journal of Biological and Chemical Sciences* 7: 2301–2316. <https://doi.org/10.4314/ijbcs.v7i6.11>
- Lekeufack-Folefack G.B., Abdel-Baki A.A.S., Ateba N.O.O., Fomena A. & Mansour L. 2019. Morphological and molecular characterization of *Myxobolus dibombensis* sp. n. (Myxozoa: Myxobolidae), a parasite of the African Carp *Labeobarbus batesii* (Teleostei: Cyprinidae) from Dibombe River, Cameroon. *Parasitology Research* 118: 763–771. <https://doi.org/10.1007/s00436-019-06209-w>

- Lekeufack-Folefack G.B., Feudjio-Dongmo B., Fomena A., Tene-Fossog B. & Wondji M.J. 2020. An optimized protocol for Myxosporidia (Cnidaria: Myxosporea) DNA extraction for molecular studies. *Open Journal of Animal Science* 10: 378–386. <https://doi.org/10.4236/ojas.2020.103023>
- Lekeufack-Folefack G.B., Tchoutezo-Tiwa A.E., Al-Tamimi J., Fomena A., AL-Omar S.Y. & Mansour L. 2021. *Myxobolus opsaridiumi* sp. nov. (Cnidaria: Myxosporea) infecting different tissues of an ornamental fish, *Opsaridium ubangiensis* (Pellegrin, 1901), in Cameroon: morphological and molecular characterization. *European Journal of Taxonomy* 733: 56–71. <https://doi.org/10.5852/ejt.2021.733.1221>
- Lekeufack-Folefack G.B., Feudjio-Dongmo B., Tene-Fossog B., Fomena A., Wondji C.S., Al-Tamimi J., Yurakhno V.M. & Mansour L. 2022. Morphological and molecular characterization of *Myxobolus nkondjockei* sp. nov. (Myxozoa: Myxobolidae), a parasite of *Labeo batesii* Boulenger, 1911 (Teleostei: Cyprinidae) from Makombè River in Cameroon. *Acta Parasitologica* 67: 1573–1583. <https://doi.org/10.1007/s11686-022-00609-2>
- Liu Y., Whipps C.M., Gu Z.M. & Zeng L.B. 2010. *Myxobolus turpisrotundus* (Myxosporea: Bivalvulida) spores with caudal appendages: investigating the validity of the genus *Henneguya* with morphological and molecular evidence. *Parasitology Research* 107: 699–706. <https://doi.org/10.1007/s00436-010-1924-9>
- Liu Y., Lövy A., Gu Z. & Fiala I. 2019. Phylogeny of Myxobolidae (Myxozoa) and the evolution of myxospore appendages in the *Myxobolus* clade. *International Journal of Parasitology* 49 (7): 523–530. <https://doi.org/10.1016/j.ijpara.2019.02.009>
- Lom J. & Arthur J.R. 1989. A guideline for the preparation of species descriptions in Myxosporea. *Journal of Fish Diseases* 12: 151–156. <https://doi.org/10.1111/j.1365-2761.1989.tb00287.x>
- Lom J. & Dyková I. 2006. Myxozoan genera: definition and notes on taxonomy, life-cycle terminology and pathogenic species. *Folia Parasitologica* 53: 1–36. <https://doi.org/10.14411/fp.2006.001>
- Mansour L., Abdel-Haleem H.M., Atwa M., Darwish A.B., Al-Quraishy S. & Abdel-Baki A.-A.S. 2021. A new myxozoan parasite, *Myxobolus allami* sp. n. (Myxozoa: Myxobolidae) from the intestinal wall of *Sparidentex hasta* (Valenciennes) in Arabian Gulf. *Folia Parasitologica* 68: e017. <https://doi.org/10.14411/fp.2021.017>
- Mirandola Dias Vieira D.H., Bravin Narciso R. & da Silva R.J. 2022. Diversity of myxozoans parasitizing the catfish *Rhamdia quelen* (Siluriformes: Heptapteridae), in southeastern Brazil, based on morphological and molecular evidence. *Scientific Reports* 12: e17596. <https://doi.org/10.1038/s41598-022-22418-3>
- Molnár K. 2002. Site preference of fish myxosporeans in the gill. *Diseases of Aquatic Organisms* 48 (3): 197–207. <https://doi.org/10.3354/dao048197>
- Molnár K., Eszterbauer E., Székely C., Dán Á. & Harrach B. 2002. Morphological and molecular biological studies on intramuscular *Myxobolus* spp. of cyprinid fish. *Journal of Fish Diseases* 25 (11): 643–652. <https://doi.org/10.1046/j.1365-2761.2002.00409.x>
- Molnár K., Marton S., Székely C. & Eszterbauer E. 2010. Differentiation of *Myxobolus* spp. (Myxozoa: Myxobolidae) infecting roach (*Rutilus rutilus*) in Hungary. *Parasitology Research* 107: 1137–1150. <https://doi.org/10.1007/s00436-010-1982-z>
- Nchoutpouen E. & Fomena A. 2011. The study of three new species of *Myxobolus* (Myxosporea: Myxobolidae) parasites of *Labeo parvus* Boulenger, 1902, cyprinid fish in Cameroon. *Journal of Applied Biosciences* 38: 2508–2517.
- Nwani C.D., Odoh G.E., Ude E.F. & Okogwu O.I. 2011. Food and feeding habits of *Gnathonemus petersii* (Osteichthyes: Mormyridae) in Anambra River, Nigeria. *International Aquatic Research* 3: 45–51.

- Okamura B., Gruhl A. & Bartholomew J.L. 2015. An introduction to myxozoan evolution, ecology and development. *In: Okamura B., Gruhl A. & Bartholomew J.L. (eds) Myxozoan Evolution, Ecology and Development: 1–20.* Springer, Cham. https://doi.org/10.1007/978-3-319-14753-6_1
- Okkay S., Gürkanlı C.T., Çiftçi Y. & Özer A. 2024. New molecular evidence on the members of the genus *Ortholinea* (Cnidaria, Myxozoa) and the description of *Ortholinea hamsiensis* n. sp. infecting the urinary bladder of European anchovy *Engraulis engrasicolus* [sic] in the Black Sea. *Parasitology* 151: 485–494. <https://doi.org/10.1017/S0031182024000325>
- Piaton E., Fabre M., Goubin-Versini I., Bretz-Grenier M.F., Courtade-Saïdi M., Vincent S., Belleannée G., Thivolet F., Boutonnat J., Debaque H., Fleury-Feith J., Vielh P., Cochand-Priollet B., Egelé C., Bellocq J.P. & Michiels J.F. 2015. Recommandations techniques et règles de bonne pratique pour la coloration de May-Grünwald-Giemsa: revue de la littérature et apport de l'assurance qualité. *Annales de Pathologie* 35: 294–305. <https://doi.org/10.1016/j.annpat.2015.05.019>
- Rácz O.Z., Székely C. & Molnár K. 2004. Intraoligochaete development of *Myxobolus intimus* (Myxosporea: Myxobolidae), a gill myxosporean of the roach (*Rutilus rutilus*). *Folia Parasitologica* 51: 199–207.
- Rambaut A. 2016. *FigTree v1.4.3*. Institute of Evolutionary Biology, University of Edinburgh, Edinburgh. Available from <http://tree.bio.ed.ac.uk/software/figtree> [accessed 28 Aug. 2025].
- Rocha S., Azevedo C., Oliveira E., Alves Â., Antunes C., Rodrigues P. & Casal G. 2019. Phylogeny and comprehensive revision of mugiliform-infecting myxobolids (Myxozoa, Myxobolidae), with the morphological and molecular redescription of the cryptic species *Myxobolus exiguus*. *Parasitology* 146: 479–496. <https://doi.org/10.1017/S0031182018001671>
- Ronquist F., Teslenko M., van der Mark P., Ayres D.L., Darling A., Höhna S., Larget B., Liu L., Suchard M.A. & Huelsenbeck J.P. 2012. MrBayes 3.2: efficient Bayesian phylogenetic inference and model choice across a large model space. *Systematic Biology* 61: 539–542. <https://doi.org/10.1093/sysbio/sys029>
- Ruxton C.H.S., Calder P.C., Reed S.C. & Simpson M.J.A. 2005. The impact of long-chain *n*-3 polyunsaturated fatty acids on human health. *Nutrition Research Reviews* 18 (1): 113–129. <https://doi.org/10.1079/NRR200497>
- Seenappa D. & Manohar L. 1981. Five new species of *Myxobolus* (Myxosporea: Protozoa), parasitic in *Cirrhina mrigala* (Hamilton) and *Labeo rohita* (Hamilton), with a note on a new host record for *M. curmucae* Seenappa & Manohar, 1980. *Journal of Protozoology* 28: 358–360. <https://doi.org/10.1111/j.1550-7408.1981.tb02866.x>
- Skelton P.H., Tweddle D. & Jackson P.B.N. 1991. Cyprinids of Africa. *In: Winfield I.J. & Nelson J.S. (eds) Cyprinid Fishes: Systematics, Biology and Exploitation: 211–239.* Chapman & Hall, London. https://doi.org/10.1007/978-94-011-3092-9_7
- Smothers J.F., von Dohlen C.D., Smith L.H. & Spall R.D. 1994. Molecular evidence that the myxozoan protists are metazoans. *Science* 265: 1719–1721. <https://doi.org/10.1126/science.8085160>
- Stiassny I.G., Teugels G.G. & Hopkins C.D. 2007. *The Fresh and Brackish Water Fishes of Lower Guinea, West-Central Africa, Volumes 1 & 2. Faune et Flore Tropicales, 42.* IRD Editions & Muséum national d'Histoire naturelle, Paris.
- Tripathi Y.R. 1952. Studies on parasites of Indian fishes, I, Protozoa Myxosporidia together with a check list of parasitic protozoa described from Indian fishes. *Records of the Zoological Survey of India* 50: 63–88. <https://doi.org/10.26515/rzsi/v50/i1/1952/162075>

Urawa S., Freeman M.A., Johnson S.C., Jones S.R.M. & Yokoyama H. 2011. Geographical variation in spore morphology, gene sequences, and host specificity of *Myxobolus arcticus* (Myxozoa) infecting salmonid nerve tissues. *Diseases of Aquatic Organisms* 96: 229–237. <https://doi.org/10.3354/dao02398>

Wolfe D. 2019. Tissue processing. In: Bancroft J.D. & Gamble M. (eds) *Bancroft's Theory and Practice of Histological Techniques*: 77–83. Elsevier. <https://doi.org/10.1016/B978-0-7020-6864-5.00006-2>

Xi B.-W., Zhao X., Li P. & Xie J. 2019. Morphological variation in *Myxobolus drjagini* (Akhmerov, 1954) from silver carp and description of *Myxobolus paratypicus* n. sp. (Cnidaria: Myxozoa). *Parasitology Research* 118: 2149–2157. <https://doi.org/10.1007/s00436-019-06350-6>

Zhang X., Liu Y., Whipps C.M., Guo Q. & Gu Z. 2019. Multiple evolutionary routes of the single polar capsule in *Thelohanellus* species (Myxozoa; Myxobolidae). *International Journal for Parasitology: Parasites and Wildlife* 8: 56–62. <https://doi.org/10.1016/j.ijppaw.2018.11.006>

Printed versions of all papers are deposited in the libraries of four of the institutes that are members of the *EJT* consortium: Muséum national d'Histoire naturelle, Paris, France; Meise Botanic Garden, Belgium; Royal Museum for Central Africa, Tervuren, Belgium; Royal Belgian Institute of Natural Sciences, Brussels, Belgium. The other members of the consortium are: Natural History Museum of Denmark, Copenhagen, Denmark; Naturalis Biodiversity Center, Leiden, the Netherlands; Museo Nacional de Ciencias Naturales-CSIC, Madrid, Spain; Leibniz Institute for the Analysis of Biodiversity Change, Bonn–Hamburg, Germany; National Museum of the Czech Republic, Prague, Czech Republic; The Steinhardt Museum of Natural History, Tel Aviv, Israël.